

## A Study on the Dimensions of Hypoglossal Canal in Southern Nigerian Crania

Osunwoke E.A (PhD-Corresponding author)

Department of Human Anatomy, Faculty of Basic Medical Sciences, College of Health Sciences, University of Port Harcourt, PMB 5323 Port Harcourt- Nigeria  
E-mail: aeosunwoke@yahoo.com

Okoseimiema S.C (M.sc)

Department of Human Anatomy, Faculty of Basic Medical Sciences, College of Health Sciences, University of Port Harcourt, PMB 5323 Port Harcourt- Nigeria  
E-mail: okosonnycity@yahoo.com

Yorkhum K.L (M.sc)

Department of Human Anatomy, Faculty of Basic Medical Sciences, College of Health Sciences, University of Port Harcourt, PMB 5323 Port Harcourt- Nigeria  
E-mail: kennethleyira@yahoo.com.

Uzomba G.C (B.sc)

Department of Human Anatomy, Faculty of Basic Medical Sciences, College of Health Sciences, University of Port Harcourt, PMB 5323 Port Harcourt- Nigeria  
E-mail: uzombagodwinchinedu@yahoo.com.

### Abstract

The hypoglossal canal is a bony canal in the occipital bone of the skull. It is the passageway for the hypoglossal nerves. This study was aimed at determining the incidence/dimensions of single and double hypoglossal canal, and if these varies with sex. 79 dry crania, out of which 55 were males and 24 females, were used for this study. A Digital Vernier caliper was used to carry out measurements on the internal and external diameters of both sides. The result indicates that there was a significant difference in the size of all the dimensions measured from the hypoglossal canal ( $P < 0.05$ ) between the male and female groups of this population. The variation is both unilaterally and bilaterally present, with bilateral single hypoglossal canal being more prevalent. In conclusion, the size of the hypoglossal canal is sex specific since there are significant differences.

**Keywords:** Incidence, hypoglossal canal, sexes, Nigeria.

### INTRODUCTION

The hypoglossal canal is a bony canal in the occipital bone of the skull. It is the passageway for the hypoglossal nerves that supplies the muscles of the tongue. Measurements of the human body whether living or non living has proven to be useful in the science of understanding human variations. The studies of non cranial variants have been a field of considerable interest to researchers especially because of their racial and regional importance (Zaidi *et al.*, 2011). Many of such variants have been observed on a racial basis and are of considerable ethnic but lesser forensic interest (Berry and Berry, 1967). Non metrical human variants including double hypoglossal canal have been studied (Berry, 1975). The hypoglossal canal was divided into two by a small bony spicule in about 28.12% of canals studied (Bhuller, 1998). Hypoglossal canal has been found to be present in all the skulls studied but was double in 43% of human skulls (Wysocki *et al.*, 2004). Apart from the hypoglossal nerve, an ample venous plexus, a small emissary vein and a branch of the ascending pharyngeal artery is present in the canal (Lang and Hornung, 1993; Leblanc, 1995; Reinhardt *et al.*, 1962; Schwaber *et al.*, 1990; Sullivan, 1961; Wysocki *et al.*, 1998). Considering such pathological symptoms as fracture of the occipital bone, intracranial and extracranial neoplasm and also congenital defects, the hypoglossal canal is of essential clinical importance (Canalis *et al.*, 1993; Lang and Hornung, 1993; Leblanc, 1995; Schwaber *et al.*, 1990; Tanzer, 1978). De Francisco *et al.*, (1990) conducted a study on anatomical variations in the hypoglossal canal of 492 dried human skulls grouped according to sex and race. Results showed that a double hypoglossal canal was observed in 97 skulls and no significant difference exists between race and sex. It may be hypothesized that the human tongue is supplied more richly with motor nerves than are those of living apes and propose that canal size in fossil hominids may provide an indication about the motor coordination of the tongue and reflect the evolution of speech and language (Richard *et al.*, 1998). The venous plexus of the hypoglossal canal creates a link between the marginal sinuses and the superior jugular bulb and indirectly with the vertebral veins (Gisel, 1956; Leblanc, 1995).

The aim of this study is to determine the incidence/dimensions of hypoglossal canal among southern Nigeria crania.

### MATERIALS AND METHODS

A total number of 79 dry human crania (consisting of 55 male crania and 24 female crania) obtained from

various Department of Human Anatomy within the universities in southern region of Nigeria were used for this study. A digital vernier caliper was used to take measurements of the anteroposterior (length) and transverse (width) diameters of the hypoglossal canal and the readings were taken twice to ensure accuracy. Skulls with any form of deformity or mutilation were not used for this study. Data was analyzed using SPSS i.e descriptive statistics and T-test.

## RESULTS

The result of this study is as presented in the tables below.

Table 1. Table showing the types of hypoglossal canal as observed in both sexes. It shows that bilateral single hypoglossal canal is prevalent over other forms of variation of the hypoglossal canals as observed in 40 male skulls and 18 female skulls as against others like unilateral double found in 7 male skulls and 6 female skulls, bilateral double hypoglossal canal found in 4 male skulls and 3 female skulls, unilateral single found in 1 male skull and non in the female skulls.

Table 2. Table showing the mean parameters measured in double hypoglossal canal of both sexes, analysis of this table shows that mean for the first external diameter(length ) in males was  $3.44 \pm 1.03\text{mm}$  while the second external diameter(width) was  $2.25 \pm 1.09\text{mm}$  on the right side. In the females, it was  $3.61 \pm 0.99\text{mm}$  for the first external diameter and  $2.67 \pm 1.21\text{mm}$  for the second external diameter on the right side also. This was statistically significant ( $P < 0.05$ ). On the left side, the first external diameter (length) was  $3.63 \pm 1.33\text{mm}$ , while the second external diameter (width) was  $2.67 \pm 1.35\text{mm}$  for males and in females it was  $3.69 \pm 1.16\text{mm}$  for the first and  $3.17 \pm 1.97\text{mm}$  for the second. There was also a significant difference ( $P < 0.05$ ) between the males and the females. The mean of the first internal diameter (length) for the males was  $3.78 \pm 0.68\text{mm}$  for the right side and  $3.45 \pm 1.21\text{mm}$  for the left while in females it was  $3.45 \pm 1.16\text{mm}$  for the right and  $3.50 \pm 1.02\text{mm}$  for the left side. The mean for the second internal diameter (width) for the males was  $2.00 \pm 1.17\text{mm}$  for the right and  $2.33 \pm 0.80\text{mm}$  for the left while in the females it was  $2.10 \pm 0.95\text{mm}$  for the right and  $2.70 \pm 2.03\text{mm}$  for the left. Figure 1. This shows double hypoglossal canal in the skull studied.

## DISCUSSION

The present study has given an insight into the cranial variants of the hypoglossal that exists in both sexes in the southern Nigerian population. It was observed that there were sex differences in the dimensions of most of the measured hypoglossal canals. Wood Jones (1933-34) was the first to propose that the differing incidences of these minor variants which occurred in different races might be useful in anthropological studies. This study has also revealed that these variants are both unilaterally and bilaterally present among the population. Berry and Berry, (1967) suggested that a wide range of these variants could be used to calculate distance statistics. It was also observed that bilateral single hypoglossal canal was prevalent over other forms of occurrence of hypoglossal canal in this population with the females having greater dimensions than the males. This study has also shown that 74.6% of the skulls studied had a single hypoglossal canal of which 72.9% is bilateral single and 1.68% unilaterally single. While double hypoglossal canal was present in 25.4% of the population studied of which 16.4% was unilaterally double and 9.0% was bilaterally double. This is in line with the research conducted by Wysocki *et al;* (2004) on the study of the hypoglossal canal of both human and other mammalian species in which they found out that 43% of the cases had double hypoglossal canal and all the skulls had hypoglossal canal though the figures from this study were higher. A study by Zaidi *et al;* (2011), also confirmed that the cranial variant (double hypoglossal canal) incident was present in 12.5% crania. Out of which in 5% crania it was bilaterally present and in 7.5% cases it was unilaterally present. In north india (U.P) the incidence of this variant was greater (12.5%) than in Nigeria (11.6%), Palestine (7%), Palestine modern (8.3%) and Burma (9.8%) and lesser in Egypt (16.6%), India (Punjab, 17.9%), North America (24%) and South America (27.4%) (Zaidi *et al.*, 2011).

## CONCLUSION

The incidence/dimensions of the hypoglossal canal have significant differences in the crania found southern Nigerian population.

The findings from this study will be relevant to anthropologists, clinicians and surgeons.

## ACKNOWLEDGEMENT

We wish to express our gratitude to the members of staff of the Department of Anatomy of the various universities visited and their laboratory attendants for their cooperation during the course of this study.

## REFERENCES

- Berry A.C, Berry R.J (1967): Epigenetic variation in the human cranium. *J Anat* 101:361-380.
- Berry, A. C (1975): Factors affecting the incidence of non- metrical skeletal variants. *Journal of Anatomy* 120: (3): 519-535.
- Bhuller A. (1998): Intracranial course and relations of the hypoglossal nerve: An anatomic study. *Surg. Radiol.*

*Anat.* ; 20:109-112.

Canalis R.F, Martin N, Black K, Ammirat M, Cheatham M, Bloch J, Becker D.P (1993): Lateral approach to tumors of the craniovertebral junction. *Laryngoscope*, 103:343-349.

De Francisco M, Lemos J.L, Liberti E.A, Adamo J, Giacomo A. L, Matson E (1990): Anatomical variations in the hypoglossal canal. *Rev OdontolUniv. Sao Paulo 4*: (1): 38-42.

Gisel A (1956): Die venen im Canalis nervi hypoglossi zeitschr *f Anat u Entwickl*, 119:257-258.

Lang J, Hornung G (1993): The hypoglossal channel and its contents in the posterolateral access to the petroclivial area. *Neurochirurgia*, 36:75-80.

Leblanc A (1995): Les nerfs craniens, Springer, Berlin, Heidelberg, 260-268.

Reinhardt K.R, Miller M.E, Evans H.E (1992): The craniovertebral veins and sinuses of the dog. *Am J Anat*, 111:67-87.

Richard F.K, Matt C, Michelle B (1998): The hypoglossal canal and the origin of human vocal behavior. *Proc Natl Acad Sci.USA*. 95:5417-5419.

Schelling F (1978): Die Emissarien des menschlichen schadels. *Anat Anz*, 143:340-382.

Schwaber M.K, Netterville J.L, Maciunas R (1990): Microsurgical anatomy of the lower skullbase- a morfometric analysis. *Am J Otol*, 11: 401-405.

Sullivan W.S (1961): The Anatomy of the rhesus monkey. Williams, Baltimore.

Tanzer A (1978): Roentgen diagnosis of hypoglossal nerve canal. *Radiologe*, 18:42-48.

Wood-jones F (1933-1934): The non metrical morphological characteristics of the skull as criteria for racial diagnosis IV. *J. Anat* 68, 96-108.

Wysocki J, Henry K, Mariusz B, Jan K, Jerzy R, Bozena S (2004): The morphology of the hypoglossal canal and its size in relation to skull capacity in man and other mammal species. *Folia Morphol* ;Pg 63(1):11-17.

Zaidi. S.H.H, Gupta R, Nema U (2011): A study of hypoglossal canal in North Indian crania, *J. Anat soc. India* 60 : (2):224-226.

Table 1: Table showing the types of hypoglossal canal as observed in both sexes.

Types	USHC	BSHC	UDHC	BDHC	Total No of single hypoglossal canals	Total No of double hypoglossal canals	Total No of hypoglossal canals measured
<b>MALE</b>	1	40	7	4	41	11	52
<b>FEMALE</b>		18	6	3	18	9	27

USHC: Unilateral Single Hypoglossal Canal.

BSHC: Bilateral Single Hypoglossal Canal

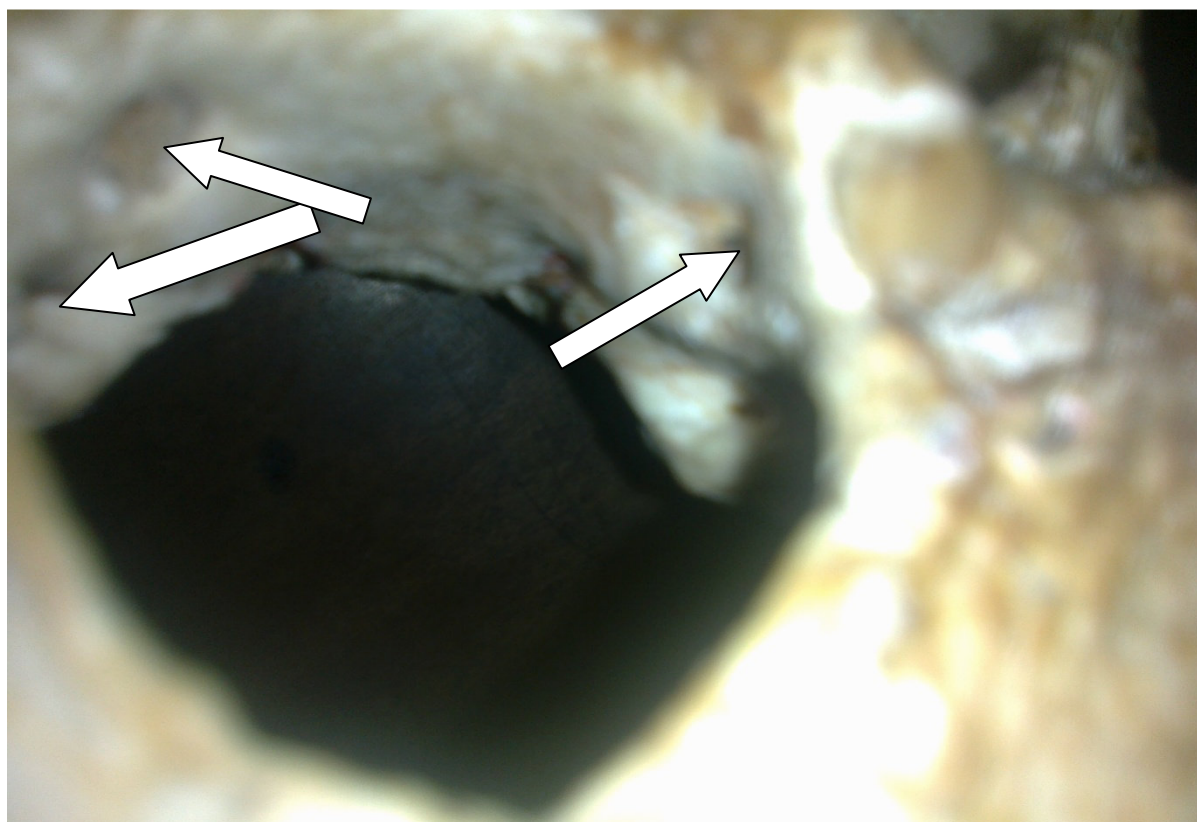
UDHC: Unilateral Double Hypoglossal Canal

BDHC: Bilateral Double Hypoglossal Canal

Table 2: Table showing the mean parameters measured in double hypoglossal canal of both sexes.

Parameters	Male		Female	
	Right	left	Right	Left
	Mean±SD (mm)		Mean±SD (mm)	
1 <sup>st</sup> External diameter	3.44±1.03	3.63±1.33	3.61±0.99	3.69± 1.16
2 <sup>nd</sup> External diameter	2.25± 1.09	2.67± 1.35	2.67± 1.21	3.17± 1.97
1 <sup>st</sup> Internal Diameter	3.78± 0.68	3.45 ± 1.21	3.45± 1.16	3.50± 1.02
2 <sup>nd</sup> Internal diameter	2.00± 1.17	2.33± 0.80	2.10± 0.95	2.70± 2.03

1<sup>st</sup> external diameter= length, 2<sup>nd</sup> external diameter= width  
1<sup>st</sup> internal diameter = length, 2<sup>nd</sup> internal diameter = width  
P< (0.05)



**Fig 1. Showing double hypoglossal canal**