

## A Study of Sacral Hiatus in Dry Human Sacra in Southern Nigeria

Osunwoke E.A (PhD-Corresponding author)

Department of Human Anatomy, Faculty of Basic Medical Sciences, College of Health Sciences, University of Port Harcourt, PMB 5323 Port Harcourt- Nigeria.  
E-mail: aeosunwoke@yahoo.com. Tel: +2348055160338.

Oladipo G. S (PhD)

Department of Human Anatomy, Faculty of Basic Medical Sciences, College of Health Sciences, University of Port Harcourt, PMB 5323 Port Harcourt- Nigeria.  
E-mail: oladipogabriel@yahoo.com. Tel: +2348038509591.

Allison T.A (MBBS)

Department of Human Anatomy, Faculty of Basic Medical Sciences, College of Health Sciences, University of Port Harcourt, PMB 5323 Port Harcourt- Nigeria.  
E-mail: doctheo4real@gmail.com. Tel: +2348096027053.

Orlu E (B.Sc)

Department of Human Anatomy, Faculty of Basic Medical Sciences, College of Health Sciences, University of Port Harcourt, PMB 5323 Port Harcourt- Nigeria.  
E-mail: endyglamour@yahoo.com. Tel: +2348130318959.

### ABSTRACT

The opening present at the caudal end of sacral canal is known as sacral hiatus. The aim of this study is to determine the anatomical variations of sacral hiatus in dry human sacra in southern Nigeria. This study was carried out on 54 dry human sacra in southern Nigeria. Various shape of the hiatus were observed which includes inverted U- shape (24.1%), inverted V-shape (33.3%), irregular (13.0%), Dumbbell (9.3%) and Bifid (5.6%). The apex of sacral hiatus was commonly found at the level of 4<sup>th</sup> sacral vertebra in 66.7%. The mean length of sacral hiatus was 23.65mm. The mean anteroposterior diameter of sacral canal at the apex of sacral hiatus was 6.11mm.

In conclusion, the sacral hiatus has anatomical variations and understanding of these variations may improve reliability of caudal epidural block.

**Keywords:** sacral hiatus, dry human sacra, southern Nigeria.

### INTRODUCTION

The opening present at the caudal end of sacral canal is known as sacral hiatus. It is formed due to failure of the fusion of laminae of the fifth sacral vertebral. It is located inferior to the fourth or third fused sacral spines or lower end of median crest. On the surface, the hiatus lies about two inches above the tip of the coccyx beneath the skin of natal cleft (Peter *et al.*, 2000). The sacral hiatus contains lower sacral and coccygeal nerve root, filum terminale external and fibro fatty tissue. A work by Sekguchi *et al.*, (2004) conducted on anatomic study of the sacral hiatus using isolated 92 sacra showed that the sacral hiatus has anatomical variations, and understanding of these variations may improve the reliability of caudal epidural block. Nagar, (2004) carried out a study on 270 sacral hiatus in dry human sacra which was observed in dumbbell shaped sacra to be (1.5%), in inverted V shape sacra, the sacral hiatus was absent in (0.7%) while it was less in 0.4%. Zarana *et al.*, (2011) carried out a study on multicentric morphometric study of 150 dry human sacrum of Indian population in Gujarat region. The results obtained was: sacral length (straight) is 11cm in 13 sacra, maximum sacral height (curved) is 11cm in 34 sacra and maximum sacral breadth is in 11cm in 99 sacra which has a significant difference. The mean distance between the hiatal apex and the dural sac has been reported to be 45-60 mm in adults and 31.4mm in children while the mean sacral space depth has been observed to be 4.6mm in adults and 3.5mm in infants (Porzionato *et al.*, 2011). Math (2010) studied 250 sacral bones to know the sexual difference, after comparing with authors, he concluded that demarking point and identification points help in sexing the sacrum with certainty and sacral index is the most useful parameter.

Anjali *et al.*, (2009) Studied 114 dry human sacral and came to the conclusion that single bony landmark may not help in locating sacral hiatus because of the anatomical variations. Depth of hiatus less than 3mm may be one of the causes for failure of the needle surrounding bony irregularities, shapes of the hiatus and defects in dorsal wall of sacral canal should be taken into epidural blocks so as to avoid its failure. A study conducted by Njihia *et al.*, (2011) on the morphology of the sacral hiatus in African population showed that the inverted V was the most

common (32.1%) shape. The apex of the sacral hiatus was at the level of the 4<sup>th</sup> sacral vertebra in 62% of cases and its mean distance from the S2 level was  $43.1 \pm 12.9$ mm whereas the anterior- posterior diameter of the sacral hiatus of the apex was  $6.4 \pm 3.1$ mm while the hiatus was absent in 1.2% cases. The level of the sacral hiatus in the African population implies minimal risk of dural puncture during caudal epidural injections.

The apex of the sacral hiatus in the low back pain patients observed at the S2 level was 46.6% in males and 54.5% in females. Patients with low back pain have a higher percentage of deficient dorsal walls in comparison to osteological findings (Vinod *et al.*, 1992). A study by Suma *et al.*, (2011) on sacral hiatus of sacral bones in southern Indian population has revealed that the apex of the sacral hiatus was commonly found at the level of 4<sup>th</sup> sacral vertebra in 77.5% of the bones studied while the base was commonly found at the level of S5 (64.38%). The maximum curvature was found commonly found at the level of S3.

This present study is aimed at determining the anatomical variations in sacral hiatus in southern Nigeria.

## MATERIALS AND METHOD

A total number of Fifty-four (54) unsexed and undamaged adult dry human sacral bones collected from the department of Anatomy of different southern Nigerian universities were used for this study. Sacra were completely ossified with no deformity. The different parameters of each sacrum were studied which includes:

1. Anteroposterior diameter of the first sacral body: this is the maximum possible diameter of body of first sacral vertebral taking one point on the anterosuperior border and other on the posteriosuperior border.
2. The shape of the sacral hiatus was noted by appearance
3. Level of apex of sacral hiatus was noted with respect to sacral vertebra.
4. The length of the sacral hiatus was measured from the midpoint of the base of apex.
5. Anteroposterior depth of sacral hiatus of the apex is measured.
6. The transverse width of sacral hiatus at the apex is measured between the inner aspects of inferior limit of sacral cornua with the help of digital vernier calipers.

Digital vernier caliper and a pair of dividers were used to measure the length and the width, while a broom stick was used to determine the anteroposterior diameter of the sacral canal. Data was analyzed using descriptive statistics and frequencies.

## RESULTS

The result of this study is as shown in the tables below.

Table 1 shows the shape of sacral hiatus; the shape of the sacral hiatus as observed were mostly the inverted V-shape 18(33.1%) and the inverted U- shape in 13 (24.1%) sacra, dumbbell shape in 5(9.3%) sacra, Bifid shape in 3(5.6%) sacra, Elongated shape in 8(14.8%) sacra and the irregular shape in 7(13.0%) sacra.

Table 2 shows the level of the apex and base of sacral hiatus; the level of apex of sacral hiatus was found to be most common at the 4<sup>th</sup> sacral vertebra in 36 (66.6%) sacra and also at 3<sup>rd</sup> sacral vertebra in 11 sacra bones (20.4%), the apex was also found at the level of 2<sup>nd</sup> sacral vertebra in 3 sacra bone (5.9%) and S5 in 4 sacra bone (7.4%), while the level of base was common at the 5<sup>th</sup> sacra vertebra in 32 (59.3%) sacra and also at the coccyx in 16 (29.6%) sacra bone and 4<sup>th</sup> sacra vertebra in 6 (11.1%)

Table 3 shows the length, the transverse width and anteroposterior diameter of the sacral hiatus from the apex to the midpoint of the base. The length of the sacral hiatus ranged from 10.01-20.00mm in 20 (37.0%) sacra, 20.01-30.00mm in 25 (46.3%) sacra bones and it is the most common, the uncommon ones are those that range from 30.01-40.00mm and >50.00mm found in 7(13.0%), 2(3.7%) sacra bones respectively. The transverse width of sacral hiatus ranged from 5.01mm>15.00mm and the anteroposterior diameter of sacral canal at the apex ranged from 0.00 – 3.00mm in 1(1.9%)sacra, 3.10-6.00mm in 33 (61.1%)sacra, 6.01-9.00mm(35.2%) sacra, and >9.00mm which is not really common.

## DISCUSSION

The present study has shown that the shapes of sacral hiatus are variable with the most common being the inverted –V shape in 18 (33.3%) sacra followed by inverted –U shape in 13(24.1%) sacra. This was in line with the study conducted by Vinod *et al.*, (1992) in which they noted that the most common shape of the sacral hiatus is the inverted V-shape in 94 (46.55) and inverted U- shape in 60 (29.70%) but was not in line with the study conducted by Nagar (2004) in which he observed the inverted U- shape in (41.5%) and inverted V- shape in (27%) sacra. It was also observed in the present study that 5 (9.3%) sacra was found to have its outline like dumbbell which was very low when compared to the previous work by Nagar (2004) in 36 (13.3%) sacra and Vinod *et al.*, (1992) in 15(7.43%) sacra. Bifid sacral hiatus was seen in 3(5.6%) sacra in the present study which was similar with the work of Nagar (2004) in 4 (1.5%) sacra. There was complete agenesis of sacra hiatus as reported by Trotter *et al.*, (1944) in 1.8% sacra, Vinod *et al.*, (1992) in 3 (1.49%) sacra, and Nagar (2004) in 4

(1.5%) sacra. It was noted in the present study that the absence of sacral hiatus due to bony over growth which is a rare phenomenon occurred in one sacrum, which was similar to the observations made by Nagar (2004) and Vinod *et al.*, (1992). The shape of the sacral hiatus was irregular in 7 (13%) sacra in the present study which was similar to that observed by Nagar (2004) in 14.1% sacra.

The apex of the sacral hiatus was most commonly found to be at the level of the fourth sacral vertebra in 36 (66.7%) sacra which was in line with the observations by Peter *et al.*, (2000), Nagar (2004) in (55.9%) sacra, Vinod *et al.*, (1992) in (76.23%) sacra and Sekiguchi *et al.*, (2004). The base was seen at the level of the 5<sup>th</sup> sacral vertebra in 32 (59.3%) sacra in this study while in other studies conducted by Vinod *et al.*, (1992) it was noted in 168 (83.17%) sacra and Nagar (2004) in 191(72.6%) sacra of the 270 sacral bones studied in Gujarat state.

The length of hiatus varied from 11-50mm in the present study which was similar to the previous work by Kumar *et al.*, (1992) in which the mean length of the sacral hiatus was 20mm. similar results were also noted by earlier studies of Trotter *et al.*, (1944) in which the length of hiatus varied from 0-60mm with a mean value of 22.5mm.

In this study, the sacral hiatus had a diameter of less than 3mm which is higher than that of the earlier studies by Trotter *et al.*, (1947) who reported 5% cases with 0-2mm in diameter. It was also noted that the transverse width varied from 5.0-15mm, in more than half (70.4%) cases, transverse width of sacral hiatus at base was (>15mm) and in 18.5% cases transverse width was from 10-15mm which was similar to the study conducted by Nagar (2004) which ranged from 3mm-19mm and in more than half 54% cases it was 10-15mm and in 84% cases it was from 6-15mm. Trotter *et al.*; (1944) who noted the transverse width to vary from 7-26mm, was higher compared to the present study. Sekiguchi *et al.*; (2004) have reported a low arithmetic mean of transverse width to be 10.22mm this may be because they noted the average distance between the sacral cornua.

#### CONCLUSION

The present study has provided an insight into the relevance of the different positions of the sacral hiatus. The knowledge of anatomical variations of sacral hiatus is important during administration of caudal epidural anesthesia and may help to improve its success rate.

This study is recommended to surgeons and anesthesiologists because of its relevance during caudal epidural anesthesia.

#### ACKNOWLEDGEMENT

We wish to express our profound appreciation to the members of staff of the Department of Anatomy of the various universities attended and their laboratory attendants for their cooperation during the course of this study.

#### REFERENCES

- Anjali A, Aditya A, Daisy S, Harjeet (2009): Morphometry of sacral hiatus and its clinical relevance in caudal epidural block. *Surgical radiological anatomy*. 31:793-800.
- Math SC, Nandyal VB, Shetty VB, Pawar (2010): Study of sexual dimorphism in human sacrum in North Karnataka. *Indian journal of forensic medicine and pathology*. 3:1320.
- Nagar SK (2004): A study on sacral Hiatus in dry human sacra. *JASI*: 53 (2): 18-21.
- Peter L W (2000): Gray's anatomy 38<sup>th</sup> edition Churchill Livingstone; 592-531 and 673-674
- Porzionato A, Veronica M, Anna P, Raffaele D.C (2011): Surgical anatomy of the sacral hiatus for caudal access to the spinal canal. *ACTA NEUROCHI. Suppl*; 108:1-3.
- Senoglu N, Oksuz H, Gumusalam, K..Z, Yuksel B, Zencirci M, Ezberci E, Kizilkanat (2005): Landmarks of the sacral hiatus for caudal epidural block: an anatomical study. *Br J Anaes*, 95(5):692-695.
- Sekiguchi M, Yabuki S, Saton K, Kikuchi S (2004): An anatomical study of the sacral hiatus: a basis for successful caudal epidural block. *Clin J. pain*; 20(1):51-54.
- Trotter M, Lanier P F (1945): Hiatus canalis sacralis in American whites and negros. *Human Biology*; 17:368-381.
- Vinod K, Pandey S N, Bajpai R N, Jain P N, Longia G S (1992): Morphometrical study of sacral hiatus. *Journal of Anatomical Society of India*; 41(1): 7-13.
- Zarana Patel D K, Thummar D, Rathod SP, Singel T C (2011): Multicentric Morphometric study of dry human sacrum of Indian population in Gujarat Region. *NJIRM*, (2):31-35.

Table 1: Table showing the shape of sacral hiatus

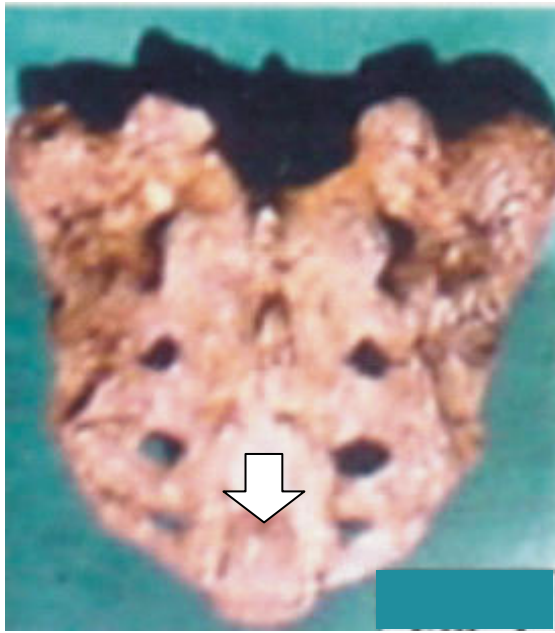
S/No	SHAPE	FREQUENCY	PERCENTAGE %
1	Inverted U-Shape	13	24.1
2	Inverted V-Shape	18	33.1
3	Dumbbell Shape	5	9.3
4	Bifid Shape	3	5.6
5	Elongated Shape	8	14.8
6	Irregular Shape	7	13.0
7	Total	54	100.0

Table 2: Table showing the position of apex and base of the sacral hiatus.


S/No	VERTEBRA	FREQUENCY	PERCENTAGE %
<b>APEX OF SACRAL HIATUS</b>			
1	2 <sup>nd</sup> Sacral vertebra	3	5.6
2	3 <sup>rd</sup> Sacral vertebra	11	20.4
3	4 <sup>th</sup> Sacral vertebra	36	66.6
4	5 <sup>th</sup> Sacral vertebra	4	7.4
	Total	54	100.0
<b>BASE OF THE SACRAL HIATUS</b>			
1	Coccyx	16	29.6
2	4 <sup>th</sup> Sacral vertebra	6	11.1
3	5 <sup>th</sup> Sacral vertebra	32	59.3
	Total	54	100

Table 3: Table showing the length, transverse width and anteroposterior diameter of sacral hiatus from apex to midpoint of base

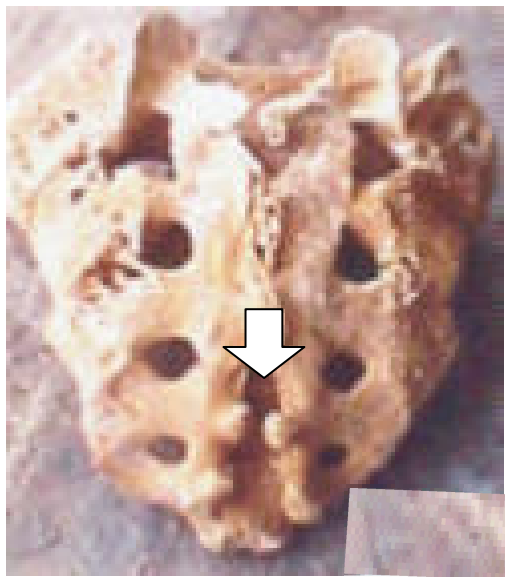
S/No	INTERVALS	FREQUENCY	PERCENTAGE %
<b>LENGTH OF THE SACRAL HIATUS</b>			
1	10.01-20.00mm	20	37.0
2	20.01-30.00mm	25	46.3
3	30.01-40.00mm	7	13.0
4	>50.00mm	2	3.7
5	Total	54	100.0
<b>TRANSVERSE WIDTH OF THE SACRAL HIATUS</b>			
1	5.01-10.00mm	6	11.1
2	10.01-15.00mm	10	18.5
3	>15.00mm	38	70.4
	Total	54	100.0
<b>ANTEROPosterior DIAMETER OF THE SACRAL HIATUS</b>			
1	0.00-3.00mm	1	1.9
2	3.10-6.00mm	33	61.1
3	6.01-9.00mm	19	35.2
4	>9.00mm	1	1.9
	Total	54	100.0



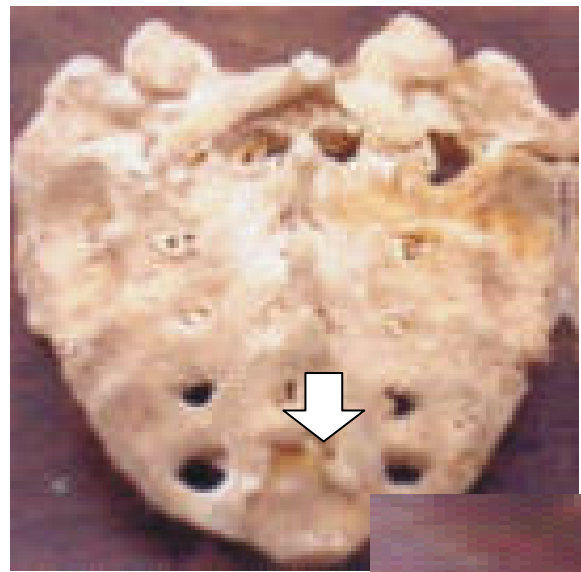
**Fig 1. Inverted U shaped sacrum.**



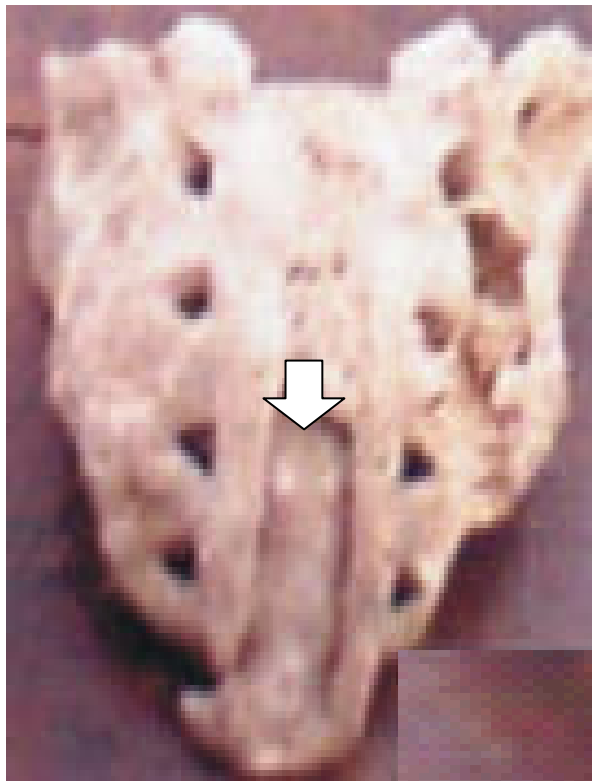
**Fig 2. Inverted V shaped sacrum.**




**Fig 3. Dumbbell shaped sacrum.**



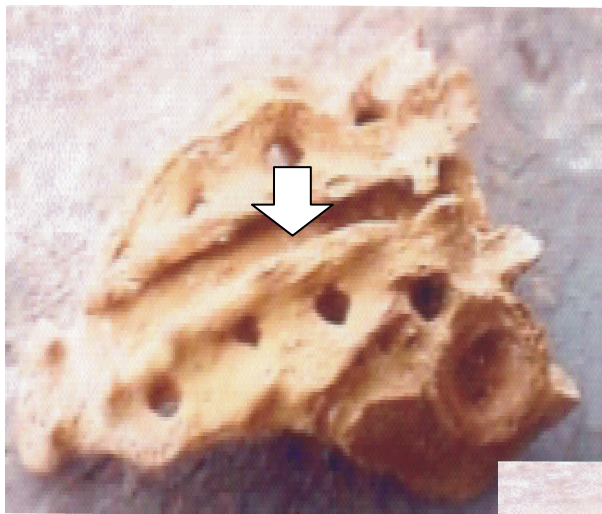
**Fig 4. Irregular shaped sacral hiatus**



**Fig 5. Elongated shaped sacrum**



**Fig 6. Bifid shaped sacrum.**



**Fig 7. Agenesis of the sacral hiatus.**